

A Thesis
For The Degree of Master of Veterinary Science

Hyperthermia aggravates Neuronal Apoptosis following Global Ischemia in Gerbils



110783
제주대학교 중앙도서관
JEJU NATIONAL UNIVERSITY LIBRARY

Graduate School, Cheju National University
Department of Veterinary Medicine

Shinmi Park

Hyperthermia aggravates Neuronal Apoptosis following Global Ischemia in Gerbils

Shinmi Park

(Supervised by Professor Myung-bok Wie)

A thesis submitted in partial fulfillment of the requirements for the degree of Master of Veterinary Science.

2001. 4.



This thesis has been examined and approved.

제주대학교 중앙도서관
JEJU NATIONAL UNIVERSITY LIBRARY

Thesis director,
Taekyun Shin, Prof. of Veterinary Medicine

Junhong Park, Prof. of Veterinary Medicine

Myungbok Wie, Prof. of Veterinary Medicine

2001.6.

**Department of Veterinary Medicine
GRADUATE SCHOOL
CHEJU NATIONAL UNIVERSITY**

Abstract

Hyperthermia aggravates Neuronal Apoptosis following Global Ischemia in Gerbils

Advised by professor Myung-bok Wie

Shinmi Park

Department of Veterinary Medicine

Graduate School, Cheju National University, Cheju, Korea



제주대학교 중앙도서관
JEJU NATIONAL UNIVERSITY LIBRARY

Brain hyperthermia has been known to be implicate in the exacerbated damage of neuronal cells during ischemic insult or recirculation. In this study, we examined whether and how hyperthermia (39°C) affects the neuronal apoptosis according to the difference of brain regions such as hippocampus, thalamus, neocortex, piriform cortex at an early reperfusion stage.

Bilateral common carotid arteries occlusion (CCAO) was induced in gerbils for 5 min during which brain temperature was maintained at either 37°C (normothermia) or 39°C (hyperthermia) followed reperfusion for 48 h. Apoptotic cell death was evaluated by terminal deoxyribonucleotidyl transferase-mediated dUTP-biotin nick end-labeling (TUNEL) and Bax,

pro-apoptosis member. In addition, we evaluated the state of astrocyte or microglial cells including inducible nitric oxide synthase (iNOS), endothelial nitric oxide synthase (eNOS) and neuronal nitric oxide synthase (nNOS) within the same brain areas. The numbers of TUNEL-positive neurons were increased within neocortex and hippocampus in hyperthermic (HT) animals, but not in normothermic (NT) and sham-operated animals at 48 h after reperfusion. The numbers of Bax-positive neurons were increased within the hippocampus, thalamus, neocortex and piriform cortex in HT animals, but not within neocortex and piriform cortex in NT animals. The glial fibrillary acidic protein (GFAP) immunoreactivity of HT animals was increased in the hippocampal region compared with that of NT animals. In contrast with NT animals, the intensive activation of microglial cells by isolectin B4 histochemistry could be seen in the hippocampus, thalamus and neocortex region in HT animals. The nNOS-positive cells between the HT and NT animals were not changed in these regions. However, the iNOS- and eNOS-positive cells (abundantly in neuron) were highly increased within the hippocampal CA1 region in HT animals.

Therefore, our results suggest that hyperthermia may be one of the crucial factors in acceleration of the neuronal apoptosis by the elevation of iNOS expression through the activation of microglia and astrocyte after ischemic injury.

Key words: global ischemia, hyperthermia, apoptosis, TUNEL, Bax, iNOS, astrocyte, microglia

CONTENTS

1.Introduction	-----	1
2.Materials and Methods	-----	3
3.Results	-----	6
4.Discussion	-----	16
5.References	-----	19



제주대학교 중앙도서관
JEJU NATIONAL UNIVERSITY LIBRARY

1. Introduction

The brain has been known as an organ which is extremely sensitive to ischemia and reperfusion injury. The vulnerability of brain cells differs according to the neuronal populations. In the hippocampus of both humans and rodents, pyramidal neurons in the CA1 region are selectively vulnerable to transient ischemia, and cell death of these neurons occurs gradually days after reperfusion (Kirino and Sano, 1984). Transient global ischemia in the four-vessel occlusion model in the rat, results in reduction of the blood flow (Pulsinelli *et al.*, 1982) and causes neuronal death in the neocortex, in the striatum and hippocampus, which are the most vulnerable areas to ischemia (Pulsinelli and Brierley, 1979).

Two distinct processes of cell death, necrosis and apoptosis, can be recognized. Necrosis is a passive form of cell death and results from injury. Apoptosis, on the other hand, is an active form of cell death initiated by the cell on the basis of information from its developmental history, from the environment or from its genome. Apoptosis is important in the pathogenesis of several nervous system diseases (Barr and Tomei, 1994; Thompson, 1995; Nijhawan *et al.*, 2000).

It is established in well-characterized rodent models that hypothermia during a period of transient global ischemia attenuates the neuronal injury, while temperature elevation exacerbates damage (Busto *et al.*, 1987; Welsh *et al.*, 1990; Minamisawa *et al.*, 1990). Brain hypothermia has been reported to reduce cerebral metabolic rate (Lanier, 1995; Mori *et al.*,

1998), oxygen consumption (Mori *et al.*, 1998), intracranial pressure (Burger *et al.*, 1998) and hydroxyl radical production (Kil *et al.*, 1996). On the other hand, hyperthermia during the transient ischemia exacerbates ischemia-induced neuronal death in hippocampal CA1 neurons (Dietrich *et al.*, 1990; Kil *et al.*, 1996). Production of reactive oxygen species (Kil *et al.*, 1996), hydroxyl free radicals (Globus *et al.*, 1995), calcium influx into neurons (Choi, 1998) and vascular permeability (Dietrich *et al.*, 1991) has been reported to be accelerating by hyperthermia. However, the expression of apoptotic factors, Bax and P53 and apoptotic cell death in global ischemia following hyperthermia remains inadequately defined.

In this study, we examined whether and how hyperthermia affects the neuronal apoptosis according to the difference of brain regions such as hippocampus, thalamus, neocortex and piriform cortex at 48 h after reperfusion using an immunohistochemical method. Thus, we surveyed the influence of hyperthermia on the expression of Bax, nNOS, iNOS, eNOS, GFAP and Isolectin B4 during global ischemia in gerbils.

2. Materials and Methods

2.1 Animals

Female Mongolian gerbils (50-60g) were obtained from the Korea Research Institute of Bioscience and Biotechnology, KIST (Taejeon, Korea).

2.2. Induction of cerebral ischemia

The female Mongolian gerbils (*Meriones unguiculatus*) weighing 50-60g were used in this study. Gerbils were anesthetized with chloral hydrate (400mg/kg, i.p.). In the supine position, a middle ventral incision was made in the neck. Both common carotid arteries (CCAs) were exposed, separated carefully from the vagus nerve. Gerbils underwent 5min of CCAs occlusion during which rectal temperature was maintained at either 37°C (normothermia, n=6) or 39°C (hyperthermia, n=6). Blood flow during the occlusion and reperfusion after removal of the clips was confirmed visually and the incision was closed. Rectal temperature was monitored for 3-4 h during reperfusion. The gerbils were sacrificed 48 h after ischemia. They were deeply anesthetized with pentobarbital (65mg/kg, i.p.) and transcardially perfused for fixation with ice-cold 4% paraformaldehyde in 0.1M phosphate buffer solution, pH 7.4(PBS). The brain were removed from the skull and fixed in the same fixative for 24-48 h. Thereafter, the brains were embedded in paraffin and representative coronal sections(6 μ m thick), which included the dorsal

hippocampus, mounted on slides and stained with 1% cresyl violet.

2.3. Immunohistochemistry

Immunohistochemical procedures were carried out using an avidin-biotin complex kit (Vector Laboratories, Burlingame, CA) by following the instruction from the manufacturer. Briefly, 6 μ m sections of the brain were deparaffinized, and treated with 0.3% hydrogen peroxide in deionized water for 30min to block endogenous peroxidase. After three washes in phosphate buffer, the sections were exposed to normal goat serum. Adjacent sections were then incubated with primary antibodies of rabbit anti-Bax (Upstate Biotechnology, Waltham, MA), mouse anti-nNOS (Transduction Laboratories, Lexington, KY), mouse anti-eNOS (Transduction Laboratories, Lexington, KY), mouse anti-iNOS (Transduction Laboratories, Lexington, KY), mouse anti-GFAP (DAKO, High Wycombe, UK) diluted in PBS for 1h at room temperature. After washing, the sections were sequentially treated with biotinylated secondary antibody and avidin-biotin complex (Vector) for 45min each. Immunolabeling was visualized using 3, 3'-diaminobenzidine (DAB, Vector), and finally counterstained with hematoxylin.

2.4. Lectin histochemistry

Microglia cells were histochemically stained with peroxidase-labeled isolectin-B4 from *Griffonia simplicifolia* (Sigma, St. Louis, MO). The isolectin is a marker discriminating microglia from other glia cells. Briefly, the sections were incubated with the isolectin (100 μ g/ml) in PBS for 1 h

at room temperature. Then, the sections were reacted with 3, 3'-diaminobenzidine (Vector) and counterstained with hematoxylin.

2.5. Terminal deoxynucleotidyl transferase (TdT)-mediated dUTP nick end-labeling (TUNEL)

DNA fragmentation was detected by in situ nick end-labeling, as described in the manufacturer's instructions (Calbiochem, Lajolla, CA). In brief, the paraffin sections were deparaffinized, rehydrated, and washed in Tris-buffered saline (TBS). The sections were treated with 0.05% pronase for 30 min at room temperature, and blocked with 0.3% hydrogen peroxide in methyl alcohol for 10 min and washed with TBS. Tissue were incubated with equilibration buffer for 20min and reacted with TdT enzyme for 1.5 h at 37°C, and then reaction was stopped in stop buffer for 5 min. Finally, sections were reacted with peroxidase-labeled anti-digoxigenine antibody for 30 min. Positive cells were visualized using a diaminobenzidine substrate kit and counterstained with hematoxylin.

3. Results

The overall results of immunohistochemistry and TUNEL staining are summarized in Table 1.

The sham-operated animals showed no evidence of neuronal death and had an average neuronal density (Fig. 1A, 1B). The gerbils in the normothermic (NT) animals and hyperthermic (HT) animals showed neuronal damage in the CA1 sector. In the cell bodies and nuclei of pyramidal neurons within the CA1 hippocampus of NT animals there appeared a massive necrotic swelling morphology (Fig. 1C, 1D). However, in HT animals, the neuronal damage was not restricted to the CA1 region but also involved the CA2-CA4 regions including dentate granule neurons (Fig. 1E, 1F). Moreover, almost the whole cytosolic membrane of neurons were already ruptured and irreversibly damaged (Fig. 1E, 1F). Increasing brain temperature 2°C during the ischemic insult extensively increased the extent and severity of hippocampal damage at 48 h after reperfusion. Thus, we detected DNA fragmentation to clarify the extent of damage.

The TUNEL staining was highly expressed within the cell nuclei in all areas of the hippocampus, dentate gyrus and neocortex in HT animals (Fig. 2B, 2D). However, in NT animals, the TUNEL-positive neurons were not detected (Fig. 2A, 2C). The TUNEL staining was evident in the hippocampus and neocortex where many neurons were already dead.

In sham-operated animals, we could not observe the immunostaining of Bax protein. In the hippocampal CA1-CA3 region and thalamus of NT

animals, the number of Bax-positive neurons were a few. (Fig. 3A, 3C), not in piriform cortex (Fig. 3E) at 48hr after reperfusion. In HT animals, the Bax expression was increased in the CA2, 3 (Fig. 3B), thalamus (Fig. 3D) and piriform cortex (Fig. 3F).

Astrocytes that defined by GFAP immunoreactivity in sham-operated animals appeared to be completely normal (Fig. 4A). On the other hand, the GFAP immunoreactivity remarkably increased in the hippocampal region that underwent hyperthermic injury (Fig. 4C). The increased staining may be due to an enlargement of the GFAP-positive cell bodies and processes, as well as to an increase in the actual number of GFAP-positive cells when compared to astrocytes in sham-operated animals. However, in NT animals, the extent of GFAP immunoreactivity increased less than that of HT animals (Fig. 4B). After 48h reperfusion, strong microglial activation could be seen in the hippocampal region, thalamus (Fig. 5) and neocortex in HT animals. In NT animals, the microglia were only rarely and weakly stained with isolectin B4 (Fig. 5). However, activated microglia were not observed in sham-operated animals.

In case of the nNOS, the staining was restricted to the neocortex in all animals. The eNOS was normally expressed in all regions of brain. The extent of eNOS expression especially in hippocampal neuron and neocortex was higher than that of other regions in sham-operated animals. However, in NT animals, the extent of eNOS expression was increased in hippocampal areas compared with that of sham operated animals. Between NT and HT animals, eNOS immunoreactivity of HT animals more increased than that of NT animals. (Fig. 6A, 6B). In sham-operated

animals, we could not observe the iNOS-positive cells in all brain regions. Similarly, the iNOS expression in NT animals was only found in neocortex region. Interestingly, we found massive expressed neurons of iNOS, restricted within the hippocampal CA1 region in HT animals (Fig. 6C, 6D).



Table 1. The expression of nNOS, eNOS, iNOS, Bax, GFAP, Isolectin B4 and DNA fragmentation after 5min CCAs occlusion.

	nNOS	eNOS	iNOS	GFAP	Isolectin B4	Bax	DNA fragmentation
Sham							
Hippocampus CA1	-	+	-	+	-	-	-
Hippocampus CA2.3	-	+	-	++	-	±	-
Thalamus	-	+	-	+	-	-	-
Neocortex	+	++	-	+	-	±	-
Piriform Cortex	-	+	-	+	-	-	-
Normothermia							
Hippocampus CA1	-	++	-	++	±	+	-
Hippocampus CA2.3	-	++	-	++	+	+	-
Thalamus	-	+	-	+	-	+	-
Neocortex	+	+++	±	+++	±	±	-
Piriform Cortex	-	+	-	++	-	-	-
Hyperthermia							
Hippocampus CA1	-	+++	++	+++	+	+	+++
Hippocampus CA2.3	-	+++	-	+++	++	+++	+++
Thalamus	-	+	-	++	+++	+++	+
Neocortex	+	+++	+	+++	+++	+	+++
Piriform Cortex	-	+	-	++	+++	+++	-

The results of immunohistochemistry and staining reactivity of DNA fragmentation are summarized. Symbols indicate that immunoreactivity is : “ - ” not seen; “ ± ” seldom; “ + ” sparse; “ ++ ” frequent; “ +++ ” abundant

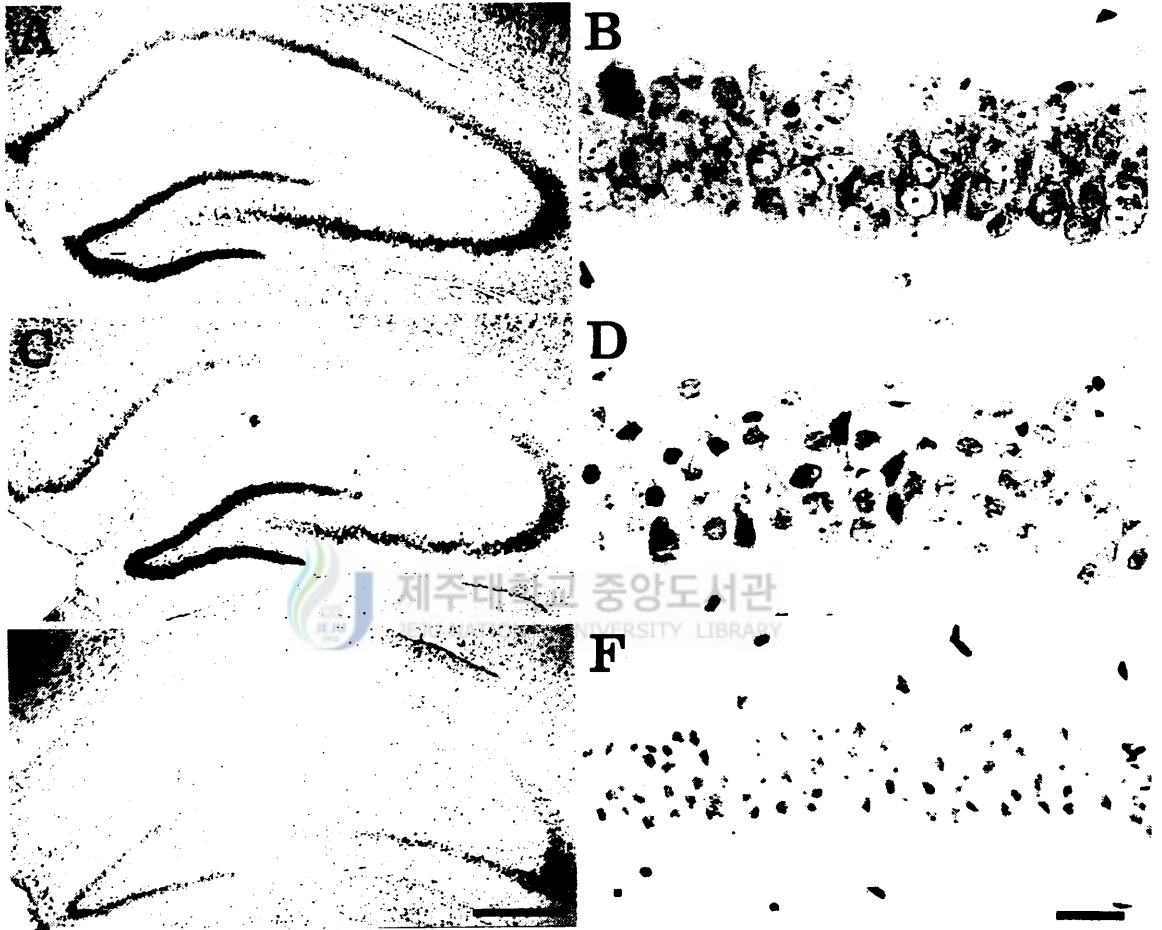


Fig. 1. Microphotographs of the ischemic hippocampal CA1 region in the gerbils, at 48 h after global ischemia (cresyl-violet staining). (A, B) Sham-operated gerbil hippocampus. (C, D) Gerbil hippocampus following intraintraischemic normothermia. (E, F) Gerbil hippocampus following intraintraischemic hyperthermia. Scale bar = 500 μ m (A, C, E) and 25 μ m (B, D, F).

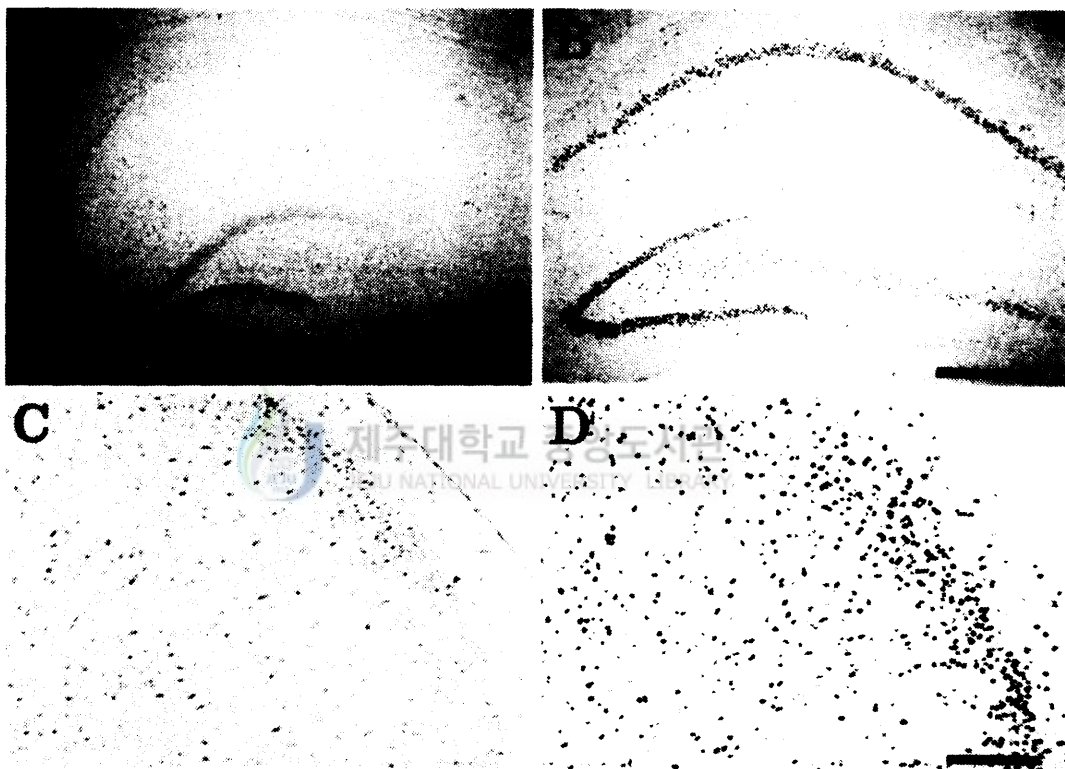


Fig. 2. Representative microphotographs of DNA fragmentation detected by TUNEL staining in the hippocampus (A, B), Cortex (C, D) at 48 h following transient forebrain in gerbils. A, C: Normothermia in gerbil at 48 h after reperfusion. B, D: Hyperthermia at 48h after reperfusion. Positive TUNEL staining is observed in the whole part of the hippocampus, dentate granule cells and cortex. Scale bar = 500 μ m (A, B) and 25 μ m (C, D).

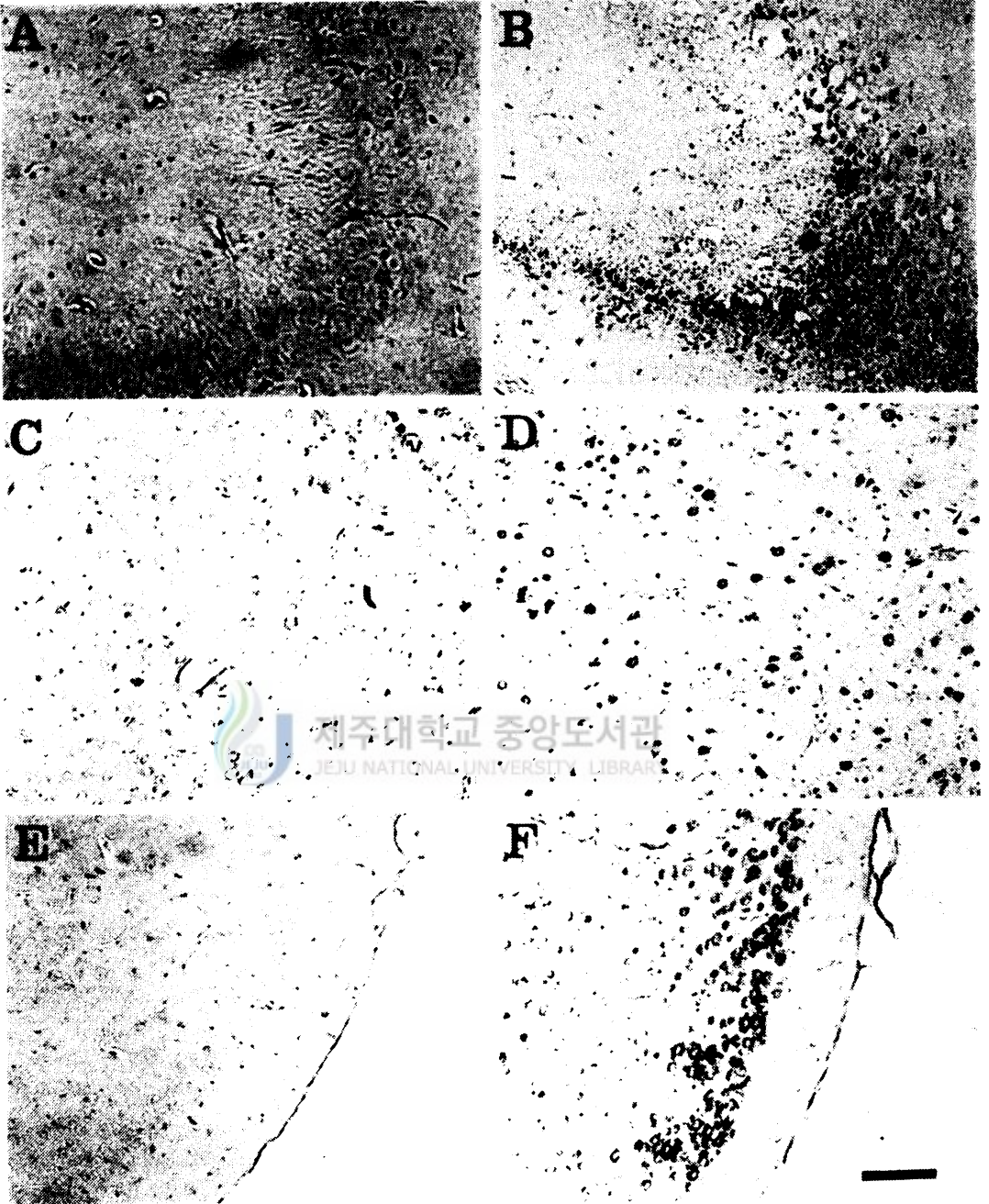


Fig. 3. Immunohistochemistry to Bax in the ischemic hippocampal CA3 region (A, B), thalamus (C, D), piriform cortex (E, F). A, C, E: Normothermic gerbil. B, D, F : Hyperthermic gerbil. Scale bar = 100 μ m.

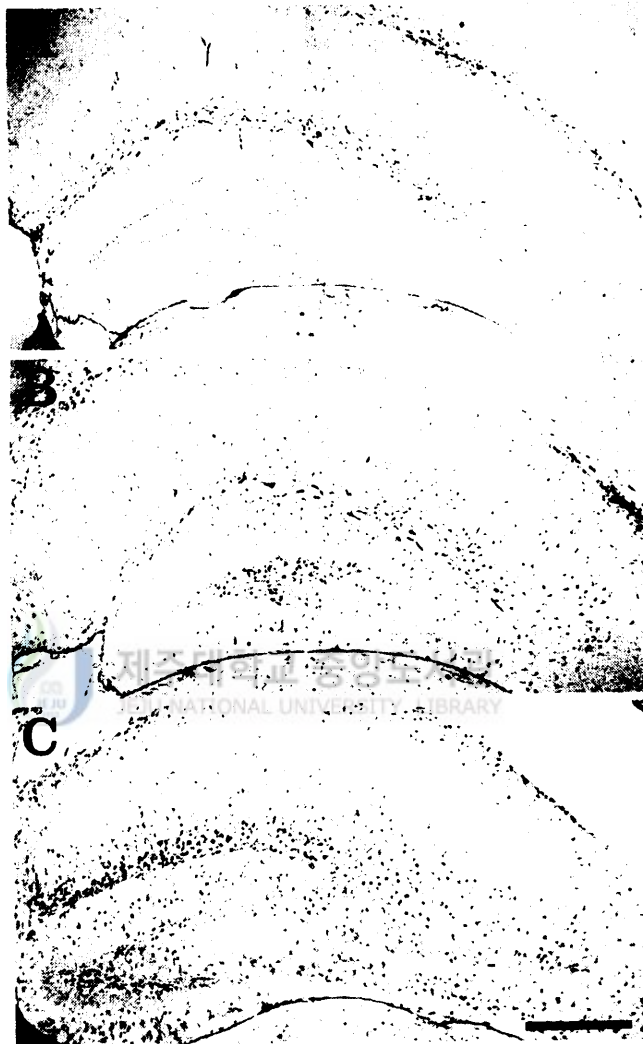

Fig. 4. Immunohistochemistry to GFAP in the ischemic hippocampal region in the gerbils at 48 h after reperfusion. (A) Sham-operated gerbil hippocampus. (B) Gerbil hippocampus following normothermia. (C) Gerbil hippocampus following hyperthermia. Note obvious increase of immunostaining of astrocytes. Scale bar = 500 μ m.

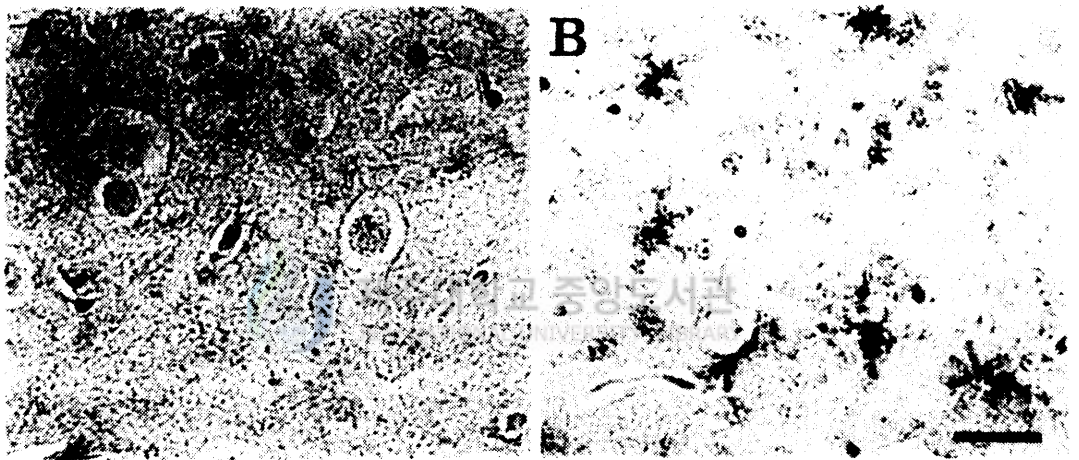


Fig. 5. Immunohistochemistry to isolectin B4 in the ischemic thalamus of normothermic and hyperthermic gerbils, at 48 h after reperfusion. A: normothermia. B: hyperthermia. Microglial activation was observed in the thalamic region in intranschemic hyperthermia. Scale bar = 25 μ m.

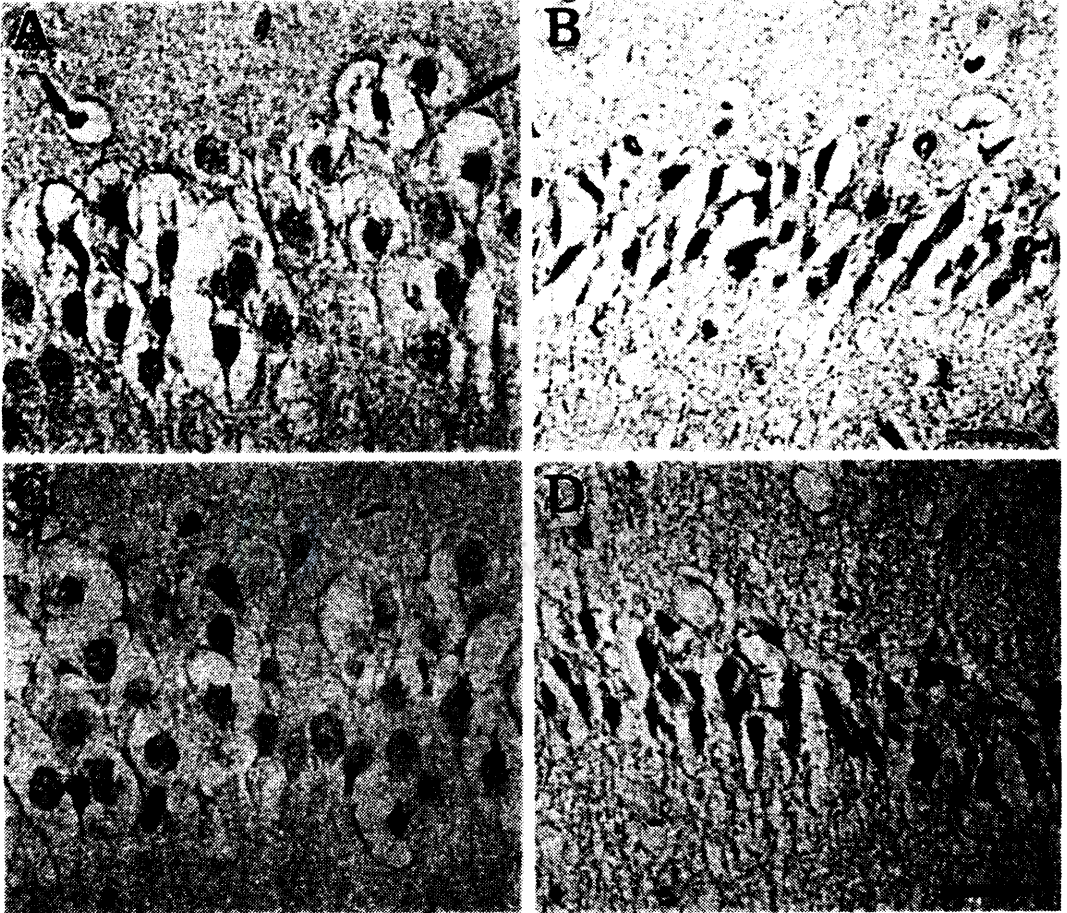


Fig. 6. Endothelial nitric oxide synthase (eNOS) (A, B) and inducible nitric oxide synthase (iNOS) (C, D) immunoreactivity in hippocampal CA1 region. A, C: normothermia, B, D: hyperthermia. Scale bar = 25 μ m.

4. Discussion

These results are generally consistent with the previous study which concluded that intraischemic hyperthermia was contributed to exacerbate on neuronal damage following ischemic injury (Dietrich *et al.*, 1990). In this study, we observed that the typical swelling of neuronal cells in the hippocampal CA1 region at 48 h after occlusion of the bilateral common carotid arteries. However, almost neuronal cells in this region were dead at 48 h in HT animals.

Many researchers have reported that TUNEL-positive cells and Bax expression are elevate in many areas during the cascade process of ischemia (Hara *et al.*, 1995; Gillardon *et al.*, 1996). In this study, we could not find TUNEL-positive cells in NT animals at 48 h after occlusion of the bilateral common carotid arteries as reported by Iwai *et al.* (1995). However, TUNEL-positive cells were broadly expressed in some other areas, such as the hippocampus, dentate gyrus, thalamus and neocortex in HT animals. Bax-positive cells, most in neurons were increased in hippocampus, thalamus and piriform cortex in HT animals, but only a few neurons were found in NT animals. It has been suggested that almost dying neurons exhibit a high expression of Bax (Krajewski *et al.*, 1995). These results suggest that the elevation of cerebral temperature, such as inflammatory diseases may contribute as one of the acceleration factor on the exacerbation of ischemic injury state (Allan, 2000).

The elevation of nNOS-positive neurons has been known at an early stage of ischemic injury, 6 h, but decreased to normal range at 72 h after

MCA occlusion (Niwa *et al.*, 2001). In this result, we observed a few nNOS-positive neurons in the neocortex at 48 h. However, there was no difference among all animals. This may be ascribed to the overpass of the observation window. eNOS was not found in the endothelium of microvessels in sham operated animals as reported by others (Niwa *et al.*, 2001). However, eNOS immunoreactivity increased more in both NT and HT animals than that of sham operated animals in neurons and endothelium cells. Between NT and HT animals, eNOS immunoreactivity of HT animals increased more than that of NT animals. As shown in previous reports, these results suggest that increased eNOS may improve the cerebral blood flow and reduce ischemia-induced cerebral infarction as a neuroprotective mechanism (Zhang *et al.*, 1994). iNOS induction in astrocyte has been known to be a consequence of ischemia-induced neuronal damage (McElhaney *et al.*, 1994). The most striking result in three NOS immunoreactivity was the detection of iNOS in neurons of the hippocampal CA1 region in HT animals. iNOS expression in neocortex was slightly increased in NT and HT animals, but there was no difference between them. This data supports that the elevation of iNOS immunoreactivity in neurons may be considered as one of the stress reactions occurring at an early stage of cerebral ischemia (Calabrese *et al.*, 2000). Moreover, iNOS is known to be concerned with the cell death in hippocampal CA1 region (Nomura, 1998).

Microglial and astroglial cells are known to activate by hyperthermia during ischemic injury. The microglial activation remarkably increased, especially in the hippocampus, thalamus, neocortex and piriform cortex in

HT animals. Activated microglia are known to be capable of releasing numerous cytotoxic agents including proteolytic enzymes, cytokines, complement proteins, reactive oxygen intermediates, NMDA-like toxins and nitric oxide (Lees, 1993).

This study demonstrates that hyperthermia during the global ischemia exacerbates the neuronal death according to the difference of brain regions. The hippocampus and neocortex were detected as very sensitive regions to the hyperthermia during ischemic injury through the iNOS production by the concurrent activation of microglia and astrocytes. Therefore, we suggest that the adequate regulation of brain temperature contributes to the survival of neuronal cells in ischemic insults.



5. References

Allan, S.M., 2000. The role of pro- and antiinflammatory cytokines in neurodegeneration. *Ann. N. Y. Acad. Sci.* 917,84-93.

Barr, P.J., Tomei, L.D., 1994. Apoptosis and its role in human disease. *Biotechnology (N Y)*. 12, 487-493.

Burger, R., Vince, H., Meixensberger, J., Roosen, K., 1998. Hypothermia influences time course of intracranial pressure, brain temperature, EEG and microcirculation during ischemia-reperfusion. *Neurol. Res.* 20, 52-60.

Busto, R., Dietrich, W.D., Globus, M.Y., Valdes, I., Scheinberg, P., Ginsberg, M.D., 1987. Small differences in intraischemic brain temperature critically determine the extent of ischemic neuronal injury. *J. Cereb. Blood Flow Metab.* 7, 729-738.

Calabrese, V., Copani, A., Testa, D., Ravagna, A., Spadaro, F., Tendi, E., Nicoletti, V.G., Giuffrida Stella A.M., 2000. Nitric oxide synthase induction in astroglial cell cultures: effect on heat shock protein 70 synthesis and oxidant/ antioxidant balance. *J. Neurosci. Res.* 60, 613-622.

Choi, D.W., 1988. Calcium-mediated neurotoxicity: relationship to specific channel types and role in ischemic damage. *Trends Neurosci.* 11, 465-469.

Dietrich, W.D., Busto, R., Valdes, I., Loor, Y., 1990. Effects of normothermic versus mild hyperthermic forebrain ischemia in rats. *Stroke*. 21, 1318-1325

Dietrich W.D., Halley, M., Valdes, I., Busto, R., 1991. Interrelationships between increased vascular permeability and acute neuronal damage following temperature-controlled brain ischemia in rats. *Acta Neuropathol. (Berl)*. 81, 615-625.

Gillardon, F., Lenz, C., Waschke, K.F., Krajewski, S., Reed, J.C., Zimmermann, M., Kuschinsky, W., 1996. Altered expression of Bcl-2, Bcl-X, Bax, and c-Fos colocalizes with DNA fragmentation and ischemic cell damage following middle cerebral artery occlusion in rats. *Mol. Brain Res*. 40, 254-260

Globus, M.Y., Busto, R., Lin, B., Schnippering, H., Ginsberg, M.D., 1995. Detection of free radical activity during transient global ischemia and recirculation: effects of intraischemic brain temperature modulation. *J. Neurochem*. 65, 1250-1256.

Hara, A., Iwai, T., Niwa, M., Uematsu, T., Yoshimi, N., Tanaka, T., Mori, H., 1995. Immunohistochemical detection of Bax and Bcl-2 proteins in gerbil hippocampus following transient forebrain ischemia. *Brain Res*. 711, 249-253.

Iwai, T., Hara, A., Niwa, M., Nozaki, M., Uematsu, T., Sakai, N., Yamada, H., 1995. Temporal profile of nuclear DNA fragmentation in situ in gerbil hippocampus following transient forebrain ischemia. *Brain Res.* 671, 305-308.

Kil, H.Y., Zhang, J., Piantadosi, C.A., 1996. Brain temperature alters hydroxyl radical production during cerebral ischemia / reperfusion in rats. *J. Cereb. Blood Flow Metab.* 16, 100-106.

Kirino, T., Sano, K., 1984. Selective vulnerability in the gerbil hippocampus following transient ischemia. *Acta Neuropathol. (Berl).* 62, 201-208.



Krajewski, S., Mai, J.K., Krajewska, M., Sikorska, M., Mossakowski, M.J., Reed, J.C., 1995. Upregulation of bax protein levels in neurons following cerebral ischemia. *J. Neurosci.* 15, 6364-6376

Lanier, W.L., 1995. Cerebral metabolic rate and hypothermia: their relationship with ischemic neurologic injury. *J. Neurosurg. Anesthesiol.* 7, 216-221

Lees, G.J., 1993. The possible contribution of microglia and macrophages to delayed neuronal death after ischemia. *J. Neurol. Sci.* 114, 119-22.

McElhaney, M.R., Chandler, L.J., Streit, W.J., 1994. Astrocytes but not microglia express NADPH-diaphorase activity after motor neuron injury in

the rat. *Neurosci. Lett.* 180, 67-70.

Minamisawa, H., Smith, M.L., Siesjo, B.K., 1990. The effect of mild hyperthermia and hypothermia on brain damage following 5,10, and 15 minutes of forebrain ischemia. *Ann. Neurol.* 28, 26-33.

Mori, K., Maeda, M., Miyazaki, M., Iwase, H., 1998. Effects of mild (33 degrees C) and moderate (29 degrees C) hypothermia on cerebral blood flow and metabolism, lactate, and extracellular glutamate in experimental head injury. *Neurol. Res.* 20, 719-726.

Niwa, M., Inao, S., Takayasu, M., Kawai, T., Kajita, Y., Nihashi, T., Kabeya, R., Sugimoto, T., Yoshida, J., 2001. Time course of expression of three nitric oxide synthase isoforms after transient middle cerebral artery occlusion in rats. *Neurol. Med. Chir (Tokyo)*. 41, 63-72.

Nijhawan, D., Honarpour, N., Wang, X., 2000. Apoptosis in neural development and disease. *Annu Rev Neurosci.* 23, 73-87.

Nomura, Y., 1998. A transient brain ischemia- and bacterial endotoxin-induced Glial iNOS expression and NO- induced neuronal apoptosis. *Toxicol. Lett.* 28, 102-103.

Pulsinelli, W.A., Brierley, J.B., 1979. A new model of bilateral hemispheric

ischemia in the unanesthetized rat. *Stroke*. 10, 267-272.

Pulsinelli, W.A., Brierley, J.B., Plum, F., 1982. Temporal profile of neuronal damage in a model of transient forebrain ischemia. *Ann. Neurol.* 11, 491-498.

Thompson, C.B., 1995. Apoptosis in the pathogenesis and treatment of disease. *Science*. 267, 1456-1462.

Welsh, F.A., Sims, R.E., Harris, V.A., 1990. Mild hypothermia prevents ischemic injury in gerbil hippocampus. *J. Cereb. Blood Flow Metab.* 10, 557-563.



Zhang, F., White, J.G., Iadecola, C., 1994. Nitric oxide donors increase blood flow and reduce brain damage in focal ischemia: evidence that nitric oxide is beneficial in the early stages of cerebral ischemia. *J. Cereb. Blood Flow Metab.* 14, 217-226.

초 록

저빌에서 전신성 뇌허혈시 고체온증이 신경세포의 Apoptosis를 악화시킴

(지도교수: 위 명 복)

박 신 미

제주대학교 대학원 수의학과

고체온증은 뇌허혈 또는 재관류 동안에 일어나는 신경세포 손상을 악화시키는데 관여하는 것으로 알려져 있다. 본 연구에서는 전신성 뇌허혈 유발시 고체온증이 해마, 시상, 신피질, 이상형피질 뇌부위 신경세포 apoptosis에 어떠한 영향을 미치는지를 관찰하였다.

저빌에서 양측 경동맥을 5분간 폐쇄하는 동안 체온은 37°C (정상온도) 또는 39°C (고체온증)를 유지하였고 48시간동안 재관류 시켰다. Apoptosis 세포사는 terminal deoxyribonucleotidyl transferase-mediated dUTP-biotin nick end-labeling (TUNEL) 방법과 apoptosis에 관여하는 인자 가운데 하나인 bax를 이용하여 평가하였다. 또한 이때 동일한 뇌 부위에서 정상세포와 미세아교세포의 변화도 관찰하였다.

TUNEL 양성 신경세포는 고체온 유발군에서 신피질, 해마, 치아이라에서 확인되었으나 정상체온군에서는 관찰되지 않았다. Bax 양성 신

경세포는 고체온 유발군의 해마, 시상, 신피질, 이상형피질 부위에서 관찰되었으나 정상체온군의 신피질과 이상형피질 부위에서는 나타나지 않았다. 고체온 유발군은 정상체온군에 비해 glial fibrillary acidic protein (GFAP) 면역반응세포수가 해마부위에서 증가하였다. 또한 정상체온군과는 대조적으로 고체온 유발군에서 isolectin B4 면역염색에 의한 미세아교세포의 강한 활성이 해마, 시상, 신피질 부위에서 관찰되었다. Endothelial nitric oxide synthase (eNOS) 양성세포는 전신성 뇌허혈시 해마부위에서 증가를 나타내었으나 정상체온군과 고체온 유발군 사이에는 별 차이가 관찰되지 않았다. 그러나 inducible nitric oxide synthase (iNOS) 양성세포는 해마CA1부위에서 정상체온군에 비해 고체온 유발군에서 뚜렷한 증가가 관찰되었다.

이상의 결과로 볼 때 전신성 뇌허혈 및 재관류로 인한 해마신경세포의 apoptosis 세포사를 고체온이 촉진시킴을 알 수 있으며 이는 부분적으로 정상세포의 활성 증가와 더불어 해마 CA1신경부위에서의 iNOS 발현증가가 기여하는 것으로 여겨진다.

주요어: 뇌허혈, 고체온, Apoptosis, TUNEL, Bax, iNOS, 정상세포, 미세아교세포

감사의 글

대학원 생활 동안 많은 격려와 힘이 되어준 분들께 감사의 글을 올립니다. 먼저 이 논문이 완성되기까지 사랑으로 가르침을 주시고 아낌없는 격려를 보내주셨던 위명복 교수님께 깊이 감사드립니다. 또한 논문 심사뿐만 아니라 논문 실험에 많은 도움을 주셨던 신태균 교수님과 박전홍 교수님께 감사의 마음을 전합니다. 그리고 대학생활동안 따뜻한 마음으로 가르침을 주신 임윤규 교수님, 이영재 교수님, 이두식 교수님, 배종희 교수님, 이경갑 교수님, 정종태 교수님, 우호춘 교수님, 김희석 교수님, 손원근 교수님께 감사드립니다. 논문 교정에 정성을 다하여 주신 Friedrich 선생님께도 감사의 마음을 전합니다.

또한 실험뿐만 아니라 대학원 생활을 활기차게 할 수 있게 도와준 실험실 식구인 현주언니, 정훈 선생님, 재욱오빠, 규범이에게 고마움을 전하며, 논문 실험에 많은 도움을 준 창종오빠, 종철오빠, 미정 뿐만 아니라 혁오빠, 성현오빠, 권태오빠, 은혜, 동식 일룡, 양나연 조교 선생님에게도 고마움을 전합니다. 그리고 나에게 많은 용기를 준 친구들, 선배님들, 후배들 모두에게 고마움을 느낍니다.

끝으로 항상 사랑으로 저를 지켜봐 주신 어머니께 그리고 물심양면으로 많이 도와주신 큰언니, 작은언니, 큰형부, 작은형부, 오빠, 이모님, 이모부님, 고모님, 고모부님, 조카 동효, 인정이에게 이 모든 결실을 드립니다.