

Intrinsic positive end-expiratory pressure caused by temporary partial upper airway obstruction in a patient with bronchiectasis

Ju Seong Park¹, So Hui Yun², Jong Cook Park²

¹Jeju National University School of Medicine,

²Department of Anesthesiology and Pain Medicine, College of Medicine, Jeju National University Hospital

(Received March 5, 2015; Revised March 12, 2015; Accepted March 20, 2015)

Abstract

We report the case of a 71-year-old female patient with bronchiectasis who developed temporary partial upper airway obstruction and intrinsic positive end-expiratory pressure (PEEP) caused by the movement of accumulated secretions from the lower respiratory tract to the upper respiratory tract because of a change in position. Changes in respiratory dynamics and the modification of extrinsic PEEP need to be considered in such patients with intrinsic PEEP. (*J Med Life Sci* 2015;12(1):1-4)

Key Words : airway management, airway obstruction, intrinsic PEEP.

Introduction

Upper airway obstruction can be caused by the presence of a tumor in a bronchus, secretions, paralysis of the vocal cords, and mass effect from an external mass^{1,2)}. This is often observed in prolonged mechanical ventilation with endotracheal intubation in cases in which the tube has a narrow internal diameter or is compressed because of mass effect, resulting in continuous discharge accumulation and fluctuation of respiratory dynamics³⁻⁵⁾.

Case Report

A 71-year-old woman (height, 162 cm; weight, 65 kg) was admitted with hypertension, bronchiectasis, dyspnea, and class II-III heart failure according to the New York Heart Association Functional Classification (NYHA Fc II-III). Pulmonary function tests performed at the pulmonology outpatient clinic showed a moderately severe obstructive pattern. Forced vital capacity was 74%, 1 s forced expiratory volume 53%, and forced expiratory flow (25-75%) 28% of the predicted values. Endotracheal intubation was performed with a reinforced tube with an internal diameter of 7.0 mm,

and mechanical ventilation was initiated (GE Datex-Ohmeda Aisys Carestation, USA). Volume-controlled ventilation was performed at 500 ml × 12 breaths/min with an inspiratory-to-expiratory time ratio of 1:2, a peak inspiratory pressure of 20 mmHg, and a fraction of inspired oxygen of 0.5. After a temporary change of position into the prone position, the patient's peak inspiratory pressure was 21 mmHg, tidal volume 500 ml, and respiratory rate 10 breaths/min. However, after approximately 15 min in the prone position, her peak inspiratory pressure increased to 29 mmHg and did not decrease even after administration of additional sedative agent. The positive end-expiratory pressure (PEEP) was temporarily set from 10 to 0, and suction was performed to remove the endotracheal secretions because grunting sounds associated with respiration had increased. PEEP was then restored to 10 and her respiratory variables were measured using a flowmeter. Changes in respiratory dynamics after applied PEEP and suction were compared with those before these procedures were performed (Fig. 1). Arterial blood gas analysis performed at the time of pressure increase indicated CO₂ retention, which subsided over subsequent follow-ups (Table 1). No remarkable hemodynamic changes were observed.

Correspondence to : Jong Cook Park
Department of Anesthesiology and Pain Medicine, Jeju National University School of Medicine,
15, Aran 13gil, Jeju-si, Jeju Special self-governing province,
Republic of Korea, 690-767
E-mail : pjcook@jejunu.ac.kr

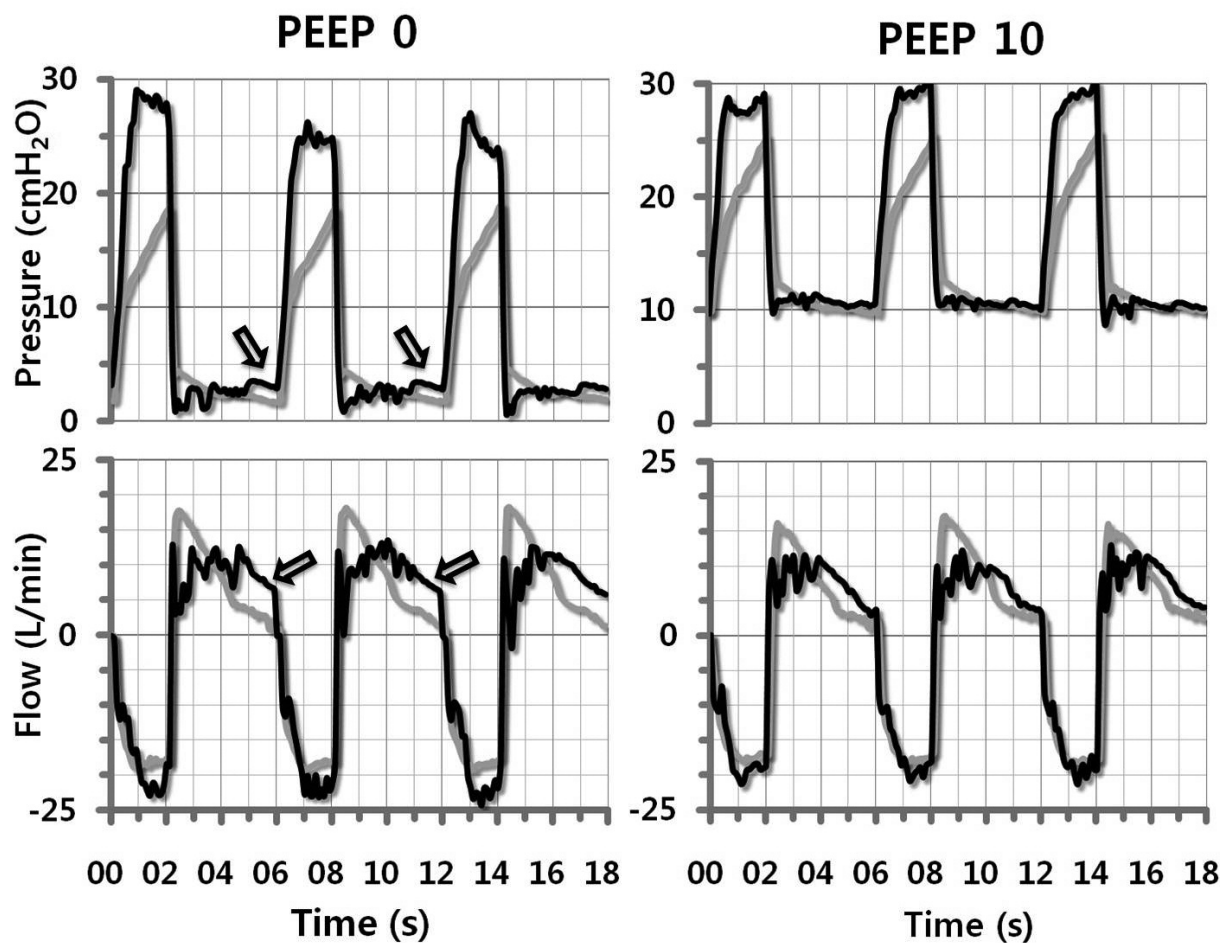


Figure 1. Airway pressure and flow waveforms for a patient receiving volume-controlled ventilation. The flow-time waveforms show persistent flow at end-expiration with intrinsic positive end-expiratory pressure (auto-PEEP). Black line: before tracheal suction, gray line: after tracheal suction, arrow: air-trapping.

Table 1. Arterial blood gas analysis.

	Before suction	After suction	Reference range
pH	7.461	7.49	7.35–7.45
pCO ₂	38.7	33.7	32.0–48.0 mmHg
pO ₂	57.6	255	74.0–108.0 mmHg
HCO ₃	27.5	26.9	21–29 mmol/L
Actual BE	3.7	2.9	-2.0–2.0 mmol/L
sO ₂ SAT	90.6	97.7	92–100%

Discussion

Upper airway obstruction is a complication that occurs in patients with thyroid disease, mediastinal tumor, and long-

term ventilation. Upper airway obstruction can lead to tachypnea, tachycardia, and changes in blood pressure. In addition, such patients may be observed to use their accessory respiratory muscles while breathing. Partial upper airway obstruction, particularly that caused by endotracheal secretions, makes weaning from the ventilator difficult and can cause serious respiratory failure requiring immediate management⁶.

A flow-volume curve is a relatively simple and noninvasive tool for the evaluation of upper airway obstruction, and enables detection of structural changes in the upper respiratory tract with good sensitivity, even in cases in which radiological and clinical examinations reveal no abnormalities⁷⁻⁹. Under normal conditions, the flow-time curve tends to slope downwards, while it tends to assume a square shape in cases of obstruction¹⁰. This abnormal shape

indicates that gas flow begins to decrease during inspiration and steadily increases at the end of expiration.

Pathological changes occurring in patients with diseases related to a narrow respiratory tract, such as asthma, chronic obstructive pulmonary disease, cystic fibrosis, and bronchiectasis, cause dyspnea and respiratory failure. These patients in particular exhibit intrinsic PEEP because of a high expiratory flow resistance and short expiratory time, and the rest period volume at the end of expiration cannot return to zero^{11,12}. A previous report showed that it takes more than 3 s for patients with obstructive lung disorders to complete one expiration.

In our patient, the flow at the end of expiration was >5 L/min and did not reach 0 before the sudden instigation of inspiration. A pulmonary function test was performed on an outpatient basis before admission, and the shape of the flow graph differed from that of other general patients and was suggestive of a severe obstructive pattern. In particular, during the entire expiration and inspiration cycle, resistance to flow was observed in the form of serrated waves, with no peak at inspiration^{10,13}. These findings indicated that the air flow was being interrupted by an obstruction in the airway, causing resistance.

Flow-volume curves of patients with normal pulmonary function show a gradual decrease in expiratory flow, while those of patients with airway obstruction show no peak at the end of inspiration; this phenomenon is known as air-trapping¹⁴. If a serrated wave is observed during both inspiration and expiration, excessive secretions should be suspected. With intrinsic PEEP, changes in respiratory mechanics are observed in respiratory cycle graphs obtained before and after suction; this is more noticeable in the absence of extrinsic PEEP (Fig. 1).

In conclusion, the findings from this case indicate that in patients with intrinsic PEEP secondary to temporary partial upper airway obstruction due to the movement of accumulated secretions from the lower to the upper respiratory tract caused by a change in position, endotracheal suction without any additional procedures can improve the dynamic respiration index.

References

- 1) Noppen M, Poppe K, D'Haese J, Meysman M, Velkeniers B, Vincken W. Interventional bronchoscopy for treatment of tracheal obstruction secondary to benign or malignant thyroid disease. *Chest*. Feb 2004;125(2):723-730.
- 2) Madan K, Bal A, Agarwal R, Das A. Malignant extra renal rhabdoid tumour presenting as central airway obstruction. *Case Rep Pulmonol*. 2014;2014:950869.
- 3) Villafane MC, Cinnella G, Lofaso F, et al. Gradual reduction of endotracheal tube diameter during mechanical ventilation via different humidification devices. *Anesthesiology*. Dec 1996;85(6):1341-1349.
- 4) Matsuo T, Colt HG. Evidence against routine scheduling of surveillance bronchoscopy after stent insertion. *Chest*. Nov 2000;118(5):1455-1459.
- 5) Kitamura Y, Shimizu K, Nagahama M, et al. Immediate causes of death in thyroid carcinoma: clinicopathological analysis of 161 fatal cases. *J Clin Endocrinol Metab*. Nov 1999;84(11):4043-4049.
- 6) Bolliger CT, Mathur PN, Beamis JF, et al. ERS/ATS statement on interventional pulmonology. *European Respiratory Society/American Thoracic Society*. *Eur Respir J*. Feb 2002;19(2):356-373.
- 7) Lucangelo U, Bernab  F, Blanch L. Respiratory mechanics derived from signals in the ventilator circuit. *Respiratory care*. Jan 2005;50(1):55-65; discussion 65-57.
- 8) Brookes GB, Fairfax AJ. Chronic upper airway obstruction: value of the flow volume loop examination in assessment and management. *J R Soc Med*. Jun 1982;75(6):425-434.
- 9) Geraghty JG, Coveney EC, Kiernan M, O'Higgins NJ. Flow volume loops in patients with goiters. *Ann Surg*. Jan 1992;215(1):83-86.
- 10) Dhand R. Ventilator graphics and respiratory mechanics in the patient with obstructive lung disease. *Respiratory care*. Feb 2005;50(2):246-261; discussion 259-261.
- 11) Ranieri VM, Grasso S, Fiore T, Giuliani R. Auto-positive end-expiratory pressure and dynamic hyperinflation. *Clin Chest Med*. Sep 1996;17(3):379-394.
- 12) Pepe PE, Marini JJ. Occult positive end-expiratory pressure in mechanically ventilated patients with airflow obstruction: the auto-PEEP effect. *Am Rev Respir Dis*. Jul 1982;126(1):166-170.
- 13) Jubran A, Tobin MJ. Use of flow-volume curves in detecting secretions in ventilator-dependent patients. *Am J Respir Crit Care Med*. Sep 1994;150(3):766-769.
- 14) Blanch L, Bernab  F, Lucangelo U. Measurement of air trapping, intrinsic positive end-expiratory pressure, and dynamic hyperinflation in mechanically ventilated patients. *Respiratory care*. Jan 2005;50(1):110-123; discussion 123-114.