

A case of juvenile dermatomyositis with esophago-pleural fistula caused by spontaneous lower esophageal perforation

Hyun Sik Kang, Hyun Joo Oh, and Kyung-Sue Shin

Department of Pediatrics, Jeju National University School of Medicine, Jeju, Korea

Abstract

Juvenile dermatomyositis (JDM) is a chronic multisystem disease characterized by nonsuppurative inflammation of striated muscle and skin. Gastrointestinal perforation including esophagus is a well-recognized complication of JDM. Corticosteroid therapy in JDM may be the cause of the ulceration and perforation of the gastrointestinal tract regardless of the disease course. We describe a rare case of a one year and nine months old girl with juvenile dermatomyositis (JDM) who developed spontaneous lower esophageal perforation with esophago-pleural fistula. Although the duration of the fistula closing was long, the fistula spontaneously obliterated without other surgical management. This is a rare case of JDM with esophago-pleural fistula caused by spontaneous lower esophageal perforation. (J Med Life Sci 2009;6:190-192)

Key Words : Juvenile dermatomyositis, esophageal perforation, esophago-pleural fistula

Introduction

Juvenile dermatomyositis (JDM) is a chronic multisystem disease characterized by nonsuppurative inflammation of striated muscle and skin. Gastrointestinal perforation including esophagus is a well-recognized complication of JDM¹⁻⁵. Although the overall prognosis of JDM is relatively good without any adverse factor, gastrointestinal perforation indicates a poor prognosis. When it sometimes rapidly leads to death, it is frequently due to underlying vasculopathy of the gastrointestinal perforation⁶.

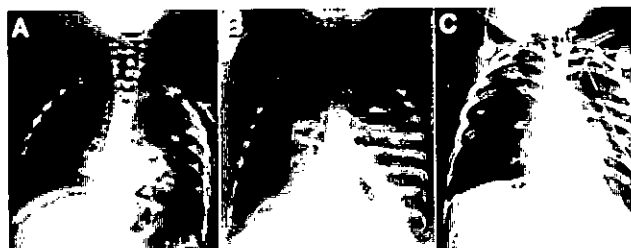
We present that a 19-year-old JDM girl with esophago-pleural fistula by spontaneous lower esophageal perforation was successfully treated with adequate drainage of perforation site and long-term hydrocortisone therapy.

Case Report

A girl, aged one year and nine months, was referred for further evaluation of respiratory distress. Three months before admission, she began to be unable to stand herself and thereafter she gradually developed muscle weakness, skin ulcerations. Two months later, she was admitted to other

hospital because she developed dysphasia to solid food, hypotonia, and aggregated skin ulcerations. At that time, physical examination showed decreased gag reflex, decreased muscle power, and skin ulcerations over left upper eyelid, right axilla, and perianal region. Laboratory findings were elevated muscle enzymes (CPK 487 IU/L, LDH 1,541 IU/L, aldolase 16 IU/L, AST 110 IU/L, ALT 48 IU/L), negative antinuclear antibody and anti-PM-Scl antibody, and negative viral markers (Coxsackie B, rubella, EBV, and measles). Muscle biopsy showed small groups of necrotic fibers, perifascicular and perivascular inflammatory cell infiltration, endomysial and perimysial fibrosis. Based on the proximal muscle weakness, elevated muscle enzymes levels, and histologic findings, a diagnosis of JDM was established according to the criteria of Bohan and Peter. After about one month, she abruptly developed respiratory difficulty, and decreased oxygen saturation. Chest plain film revealed the fluid collection of left lung field and pneumothorax (Fig 1).

Figure 1. Serial chest plain film of acute-onset dyspnea. A and B show sudden appearance of the fluid collection of left lung field and pneumothorax. C shows the fluid collection of left lung field and pneumothorax are remained after chest tube insertion.




Received : 10 July 2009, Revised: 3 August 2009, Accepted: 18 August 2009

Address for correspondence : Kyung-Sue Shin
Department of Pediatrics, Jeju National University School of
Medicine, 66 Jejudaehakno, 690-756, Jeju, Korea
E-mail : kyungsue@jejunu.ac.kr

Chest tube inserted under the impression of pyopneumothorax and she was referred to our hospital.

On admission, she was acutely ill with marked respiratory distress; respiration, 50/min and body temperature, 38°C. Findings of physical examination were decreased breath sound at left lung field, a chest tube in left hemithorax with continuous drainage, and skin ulcerations over left upper eyelid, both axilla, right post-auricular and perianal region. Muscle mass, muscle tone, and muscle power were also decreased. Laboratory studies revealed a leukocyte count of 4,860/mm³, hemoglobin of 14.1 g/dL, platelet count of 265,000/mm³, erythrocyte sedimentation rate (ESR) of 35 mm/hr, total protein 5.0 g/dL, albumin 2.3 g/dL, AST 45 IU/L, ALT 33 IU/L, CPK 70 IU/L, LDH 336 IU/L, aldolase 8.5 IU/L. She was treated with stress-dose intravenous hydrocortisone and Gram positive bacteria-directed antibiotics. The liquid diet fed via nasogastric tube. Until second hospital day, chest tube drained 1,500–1,800 mL/day. Esophagography revealed the contrast dye leaked to left pleural space through the esophagopleural fistula near the gastroesophageal junction (Fig 2). However, she could not take surgical intervention because her general condition was poor. She received total parenteral nutrition (TPN), intravenous hydrocortisone, and antibiotics with adequate drainage of perforation site. Esophagography was following up one month later and showed obliteration of the fistular tract. She began a liquid diet and later progressed to a regular diet with no subsequent problem. She was discharged after one month. On follow-up 2 months later, she was tolerating oral intake without other problems.

Figure 2. Esophagography A. The initial phase of esophagography shows the contrast dye occupies left subphrenic space and leak to left pleural space through the fistula. B. The late phase of esophagography shows the leaked dye make left pleural contour.



Discussion

Although the precise pathogenesis of JMD is unknown, recent studies suggested autoimmune play an important role in pathogenesis. Immune complex-mediated vasculitis may be an initiating factor in JMD^{7, 8)}, and the vasculopathy affects striated muscles, skin, subcutaneous tissues, and gastrointestinal tract. Gastrointestinal perforation in JMD caused by this vasculopathy can occur in any part of the gastrointestinal tract¹⁻⁵⁾. Wedgewood and et al⁹⁾ reported an underlying vasculopathy as the cause of gastrointestinal ulceration in JMD. Banker and Victor¹⁾ noted a multifocal, submucosal, and noninflammatory endoarteropathy with superimposed thrombosis was responsible for the infarcted tissues of gastrointestinal perforation.

Corticosteroid therapy in JMD may be the cause of the ulceration and perforation of the gastrointestinal tract regardless of the disease course. However, previously reported cases presented that gastrointestinal ulcerations in dermatomyositis developed before the corticosteroid therapy or after a very short time of the therapy. Moreover, gastrointestinal ulcerations have described long before the introduction of the corticosteroid therapy³⁾. The corticosteroid therapy in JMD is not regarded as an essential factor in the gastrointestinal ulceration and perforation. In this case, she was diagnosed with JMD two months before. During admission of other hospital, she was given antacid medication for the prevention of gastrointestinal ulceration and the perforation developed one month later. No definitely precipitating factors in her hospital course were attributed to esophageal perforation except disease itself.

The surgical management of gastrointestinal perforation including esophagus is dependent on location and extent of the perforation. In this case, the perforation was lower esophagus near the gastroesophageal junction with the esophago-pleural fistula. The fistula connected with left pleura throughout left subphrenic space. However, she could not take surgical management for poor condition, we chose to manage our patient by adequate drainage of perforation site, TPN, low dose hydrocortisone, and broad-spectrum antibiotics. After one month, the fistular was spontaneously obliterated without any surgical management. She was tolerating oral intake without other problems on follow-up 2 months later. Although

the duration of the fistula closing was long, the fistula spontaneously obliterated without other surgical management. This is a rare case of JDM with esophago-pleural fistula caused by spontaneous lower esophageal perforation.

Reference

1. Banker BQ, Victor M. Dermatomyositis (systemic angiopathy) of children. *Medicine* 45:261-289, 1966
2. Crowe WE, Bove KE, Levinson JE, Hilton PK. Clinical and pathogenetic implications of histopathology in childhood polydermatomyositis. *Arth Rheum* 25:126-139, 1982
3. Schullinger JN, Jacobs JC, Berdon WE. Diagnosis and management of gastrointestinal perforations in childhood dermatomyositis with particular reference to perforations of the duodenum. *J Pediatr Surg* 20:521-524, 1985
4. Inamdar S, Slim MS, Bostwick H, Godine L. Treatment of duodenocutaneous fistula with somatostatin analog in a child with dermatomyositis. *J Pediatr Gastroenterol Nutr* 10:402-404, 1990
5. Thompson JW. Spontaneous perforation of the esophagus as a manifestation of dermatomyositis. *Ann Otol Rhinol Laryngol* 93:464-467, 1984
6. Cassidy JT, Petty RE. Juvenile dermatomyositis. *Textbook of rheumatology*. 3rd ed. Philadelphia, WB Saunders. 1997:323-364
7. Spencer CH, Jordon SC, Hanson V. Circulating immune complexes in juvenile dermatomyositis. *Arthritis Rheum* 23:750- , 1980
8. Kissel JT, Mendell JR, Rammohan KW. Microvascular deposition of complement membrane attack complex in dermatomyositis. *N Engl J Med* 314:329-. 1986
9. Wedgewood RJP, Cook CD, Cohen J. Dermatomyositis. Report of 26 cases in children with a discussion of endocrine therapy in 13. *Pediatrics* 12:447-466, 1953