

# Beauveria bassiana Causing Keratoscleritis In a Patient with Adrenal Insufficiency

Jin Ho Kim<sup>1</sup>, Young Ree Kim<sup>2,3</sup>, Sun Hyung Kim<sup>2</sup>, Jin Ho Jung<sup>2</sup>, Sang Woon Lee<sup>2</sup>

<sup>1</sup>From medical course in Jeju National University School of Medicine,

<sup>2</sup>Jeju National University School of Medicine,

<sup>3</sup>Jeju National University Institute of Medical Science, Jeju, Korea

(Received April 27, 2016; Revised May 4, 2016; Accepted May 11, 2016)

## Abstract

The *Beauveria* species, well-known insect pathogens, have been used for biological insecticides. They were increasingly reported to cause human infections in worldwide, such as mycotic keratitis, disseminated infection in a patient with acute leukemia, and deep tissue infection. We introduce here a case of keratoscleritis due to the *Beauveria bassiana* in an immunocompromised patient with underlying adrenal insufficiency, degenerative arthritis, and hypertension, initially not suspected by SDA and LPCB stain and revealed by PCR and 18S rDNA sequencing as the *Beauveria* species. (*J Med Life Sci* 2016;6(1):19–21)

**Key Words :** *Beauveria*, Keratoscleritis, 18S rDNA sequencing

## Introduction

Keratoscleritis could be a very serious diseases in clinical cases and lead to endophthalmitis by the proliferations of cells in the eye and perforation of the eye, and even to blindness, if not treated properly. So, many laboratories have tried the microbiologic tests to find the cause of keratoscleritis. Diverse organisms such as bacteria, fungi, viruses, chlamydia, and parasites can cause infections of cornea and sclera. So, the rapid diagnosis of causative microorganisms and treatment must be needed to prevent disease progression and complications.

The *Beauveria* species, well-known insect pathogens, have been used for biological insecticides. They were increasingly reported to cause human infections in worldwide, such as mycotic keratitis<sup>1-3)</sup>, disseminated infection in a patient with acute leukemia<sup>4)</sup>, and deep tissue infection<sup>5)</sup>.

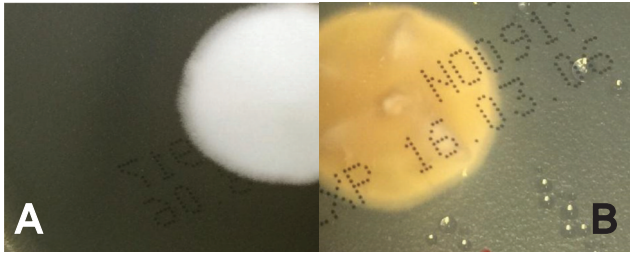
We introduce here a case of keratoscleritis due to the *Beauveria bassiana* in an immunocompromised patient with underlying adrenal insufficiency, degenerative arthritis, and hypertension, initially not suspected by SDA and LPCB stain and revealed by PCR and 18S rDNA sequencing as the *Beauveria* species.

## Case Report

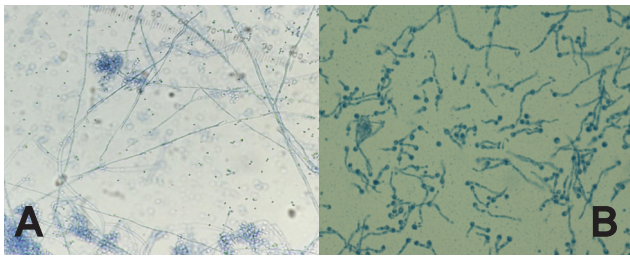
An 81-year-old woman visited our ophthalmologic outpatient clinic, complaining of severe pain and blurred vision of right eye. External photography of right eye showed choroid bulging in the right sclera and conjunctival chemosis, engorged episcleral and scleral vessels, and small perilimbal corneal infiltration adjacent to scleral lesion. She had taken the steroids for adrenal insufficiency and antihypertensive drugs for hypertension for several years. Four years ago, she had received pterygium surgery for both eyes and had taken the total knee replacement arthroplasty for degerative arthritis of left knee. Physical examination revealed no specific finding except above right eye lesion. Her visual acuity decreased and corneal ulcer and inflammation in the right anterior chamber were noted in the slit lamp biomicroscopy examination. On the Gram stain of the sample from the right eye, molds are noted, so, the specimen was cultured in Sabouraud's Dextrose Agar (SDA, Hanil KOMED, Seoul, Korea) at 30°C. On the 4th culture day, the isolate started to grow. The front surface of the Sabouraudes Dextrose Agar showed rapid growing white cottony fungus within 10 days (Fig. 1A). The reverse surface of the Sabouraudes Dextrose Agar had yellow color pigmentation after 4 and 10 days incubations (Fig. 1B). Lacto-Phenol Cotton Blue stain for microscopic examination showed cells with globose bases and extended, denticulate rachis and conidiogenous cells and conidia (Fig. 2A, 2B).

Correspondence to : Young Ree Kim  
Department of Laboratory Medicine, Jeju National University Hospital,  
Jeju National University School of Medicine, 15, Aran 13gil, Jeju-si,  
Jeju Special self-governing province, 63241, Republic of Korea  
E-mail : namu8790@jejunu.ac.kr(cpwoman@hanmail.net)

Based on the above results, the definite diagnosis and the differentiation of the organism couldn't be possible.



**Figure 1.** The front surface of the Sabourauds Dextrose Agar showed rapid growing white cottony fungus within 10 days (Fig. 1A). The reverse surface of the Sabourauds Dextrose Agar had yellow color pigmentation after 10 days incubations (Fig. 1B).



**Figure 2.** Lacto-Phenol Cotton Blue stain for microscopic examination showed cell with globose bases and extended, denticulate rachis and conidiogenous cells and conidia (Fig. 2A, 2B).

We extracted DNAs of fungus using the bead beater-phenol extraction method. We suspended a loopful of culture of each isolate in 200mL of TEN buffer (10m M Tris - HCl, 1mM EDTA, 100mM NaCl: pH 8.0), placed in a 2.0mL screw-cap microcentrifuge tube filled with 200mL (packed volume) of glass beads (diameter, 0.1mm: Biospec Products, Bartlesville, Okla.) and 200mL of Phenol:Chloroform: Isoamyl alcohol (25:24:1) (SIGMA chemical co. P-2069). We oscillated the tube on a Mini-Bead Beater (Biospec Products) for 1 min to disrupt the fungus. We centrifuged the tube at 15,000rpm, for 15min to separate the phases. After the aqueous phase was transferred into another clean tube, we added 10mL of 3M sodium acetate and 250mL of ice-cold ethanol: to enable the DNA to precipitate, we kept the mixture at  $-20^{\circ}\text{C}$  for 30min. We washed the DNA pellet with 70% ethanol, dissolved in 60mL of TE buffer (10mM Tris - HCl, 1mM EDTA, 100mM NaCl: pH 8.0) and used it as a template for PCR. We performed PCR with a set of primers (Forward primer (0817) 5'-TTAGCATGGAATAATRRRAATAGGA-3' and Reverse primer (1536) 5'-ATTGCAATGCYCTATCCCCA-3')

for amplification of the partial 18S rDNA sequences. We added 3 mL of template DNA and 20 mL of each primer to a PCR mixture tube (AccuPower PCR PreMix: Bioneer, Daejeon, Korea), which contained 1 U of Taq DNA polymerase, each deoxynucleoside triphosphate at a concentration of 250mL, 50mM Tris-HCl (pH 8.3), 40mM KCl, 1.5mM MgCl<sub>2</sub>, and gel loading dye. The reaction mixture was subjected to 35 cycles of amplification (2 min at  $94^{\circ}\text{C}$ , 10 s at  $56^{\circ}\text{C}$ , and 30s at  $72^{\circ}\text{C}$ ), followed by a 5-min extension at  $72^{\circ}\text{C}$  (model 9600 thermocycler; Perkin Elmer Cetus). We electrophoresed PCR products on a 1.2% agarose gel and purified with a QIAEX II gel extraction kit (QIAGEN, Hilden, Germany). We used Applied Biosystems model 373A automatic sequencer and a BigDye Terminator Cycle Sequencing kit (Perkin-Elmer Applied Biosystems, Warrington, United Kingdom) for the 18S rDNA analysis. Sequencing revealed *Beauveria bassiana* with forward and reverse sequencing showing 100% homology. The patient took the medications with vigamox, steroid, voriconazole, and doxycycline for 5 weeks, and then improved the conditions.

## Discussion

The national multicenter epidemiological study<sup>6)</sup> of the corneal infection showed that causative microorganisms were detected bacteria in 63.3% of infectious keratitis, fungus, 11.7%, amoeba, 2.9%. And other epidemiological study<sup>7)</sup> of patients with fungal keratitis revealed that *Fusarium* (29.0%), *Aspergillus* (24.6%), *Candida* (15.9%), *Alternaria* (10.1%), *Acremonium* (5.8%) were isolated. *Beauveria* species have been rarely identified as agents of human infections. By conventional mycological methods, identification of fungus species is often difficult. Several cases<sup>8-10)</sup> of identification by molecular methods such as ITS rDNA and LSU rDNA D1 - D2 sequencing have been reported for reliable and rapid identification of human pathological fungus. Recently, *Beauveria* species were increasingly reported to cause human infections such as mycotic keratitis<sup>1-3)</sup>, disseminated infection<sup>4)</sup>, and deep tissue infection<sup>5)</sup>. *Beauveria bassiana* grows naturally in soils and belongs to the entomopathogenic fungi, acts as a parasite on various arthropod species. So, it is being used as a biological insecticide to control a number of pests. This species is named after the Italian entomologist Agostino Bassi, who discovered it in 1815 and causes the muscardine disease which then led to carriers transmitting it by air. We introduce here a case of keratoscleritis due to the *Beauveria bassiana* in an immunocompromised patient with

underlying adrenal insufficiency, degenerative arthritis, and hypertension, initially not suspected by SDA and LPCB stain and revealed by PCR and 18S rDNA sequencing as the *Beauveria bassiana*. The rapid identification of causative fungal microorganism and proper treatment can prevent various complications even to blindness, so, the use of molecular diagnosis method for ophthalmic infection could be recommended.

## References

- 1) Kislak TA, Cu-Unjieng A, Sigler L, Sugar J. Medical management of *Beauveria bassiana* keratitis. *Cornea* 2000;19:405–6.
- 2) Low CD, Badenoch PR, Coster DJ. *Beauveria bassiana* keratitis cured by deep lamellar dissection. *Cornea* 1997;16:698–9.
- 3) Ligozzi M, Maccacaro L, Passilongo M, Pedrotti E, Marchini G, Koncan R, et al. A case of *Beauveria bassiana* keratitis confirmed by internal transcribed spacer and LSU rDNA D1–D2 sequencing. *New Microbes and New Infections* 2014;2(3):84–7.
- 4) Tucker DL, Beresford H, Sigler L, Rogers K. Disseminated *Beauveria bassiana* Infection in a Patient with Acute Lymphoblastic Leukemia. *Journal of Clinical Microbiology* 2004;42(11):5412–4.
- 5) Henke MO, Hoog GS, Gross U, Zimmermann G, Kraemer D, Weig M. Human Deep Tissue Infection with an Entomopathogenic *Beauveria* Species. *Journal of Clinical Microbiology* 2002;40(7):2698–702.
- 6) Hahn YH, Hahn TW, Tchah HW, Choi SH, Choi KY, Kim KS, et al. Epidemiology of Infectious Keratitis(II): A Multi-center Study. *J Korean Ophthalmol Soc* 2001;42(2):247–65.
- 7) Hahn YH, Lee DJ, Kim MS, Choi SH, Kim JD. Epidemiology of fungal keratitis in Korea. *J Korean Ophthalmol Soc* 2000;41:1499–508.
- 8) Lo Cascio G, Ligozzi M, Maccacaro L, Fontana R. Utility of molecular identification in opportunistic mycotic infections: a case of cutaneous *Alternaria* infection in a cardiac transplant recipient. *J Clin Microbiol* 2004;42:5334–6.
- 9) Lo Cascio G, Ligozzi M, Maccacaro L, Rizzonelli P, Fontana R. Diagnostic aspects of cutaneous lesions due to *Histoplasma capsulatum* in African AIDS patients in nonendemic areas. *Eur J Clin Microbiol Infect Dis* 2003;22:637–8.
- 10) Lo Cascio G, Ligozzi M. *Alternaria*. In: Liu D, ed. *Molecular detection of human fungal pathogens*. ISBN: 9781439812402. Boca Raton, FL: Taylor & Francis CRC Press, 2011:27–36.